

LOW LEVEL LASER THERAPY IN PATIENTS WITH VENOUS ULCERS: EARLY AND LONG-TERM OUTCOME

Y. Kleinman¹, S. Simmer¹, Y. Braksmá¹, B. Morag² and D. Lichtenstein²

1: Wound Care Clinic, Department of Internal Medicine, Bikur Holim Hospital, Jerusalem; and
2: Department of Vascular Surgery, Tel Aviv-Sourasky Medical Center, Ichilov Hospital and Sackler Faculty of Medicine, Israel

The effectiveness of low level laser therapy in accelerating wound healing has been clinically well documented. We report our experience treating 42 patients with resistant venous ulcers (*ulcus cruris*) due to chronic venous insufficiency syndrome, using low level laser therapy (LLLT). Full granulation and closure of the ulcers was achieved in 36 patients, two of whom had a recurrence after two years. Complete wound closure in 85.7% of our patients is attributed to the biostimulating effect of laser therapy.

Key words: low level laser, laser therapy, venous stasis ulcer, wound healing, *ulcus cruris*.

Introduction

Venous stasis ulcers account for up to 90% of all chronic wounds of the lower extremity.⁽¹⁾ Abnormal calf vein hemodynamics - chronic venous insufficiency - is the major pathogenesis for this condition.^(2,3) Some 14% of patients with venous dilatation, swelling and dermatitis will develop stasis leg ulcers.⁽⁴⁾ The ulcer is only the 'tip of the iceberg' however, and tissue damage extends far beyond the margins of the ulcer. Despite its frequent occurrence and the variety of treatment regimens, patients often suffer years of unsuccessful and sometimes painful or harmful treatments. Since Mester's pioneering studies in the late 1960s⁽⁵⁾ and early 1970s,⁽⁶⁾ the effectiveness of low level laser therapy (LLLT) in accelerating wound healing has been clinically documented. We describe the outcome of treatment and follow-up on the use of LLLT in patients with long-lasting venous ulcers that failed common conservative therapy.

Materials and Methods

The study group included patients referred to wound care clinics in Jerusalem and Tel Aviv from 1967 to 1995. All patients had venous ulcers for more than 6

months, and were being treated in hospital outpatient dermatology, vascular, surgery or plastic surgery clinics. Patients whose condition worsened despite conventional therapy were enrolled in the study. Excluded were those with peripheral arterial disease, haematologic abnormalities, hypercoagulable state, vasculitis, metabolic disorders that lead to ulcers, or severe congestive heart failure.

The sample included 42 patients, 10 men and 32 women, mean age 55.5 ± 3.70 years (females 55.4 ± 4.49 , men 56.0 ± 5.73 years); 28 patients had no apparent cause for varicose veins, 12 had morbid obesity, and 2 had *cor pulmonale* with right sided failure that led to *ulcus cruris*. No change was made in the patients' medication during the study, and auxiliary topical treatment was continued when appropriate.

Laser Therapy

LLLT was administered on an ambulatory basis 3 times a week, using one of the following two laser instruments:

A: A 9-diode, infrared gallium-arsenide (GaAs) continuous laser, 785 nm, 6 mW (each diode) (Medical Electronics, Germany). The laser was applied in a manual scanning mode for 20 minutes every other day in 29 patients who had a single wound on a limb.

Addressee for Correspondence:

Dr Yosef Kleinman,
Wound Care Clinic, Department of Internal Medicine,
Bikur Holim Hospital, 5 Strauss Street, Jerusalem 91004 Israel.

Manuscript received: June, 1996

Accepted for publication: July, 1996

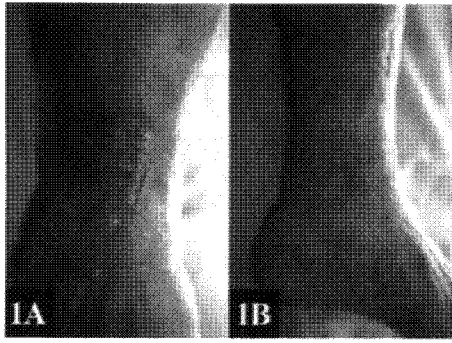


Fig 1: This 83-year-old woman had severe kyphoscoliosis-compensated *cor pulmonale*, hiatus hernia, post-myocardial infarction, and varicose veins. **A:** several venous ulcers are seen on the left leg which had been treated for 1.5 years in a surgery clinic. There was venous bleeding from one of the enlarged veins in the main ulcer. **B:** complete wound closure after 7 months of LLLT treatment. Despite the development of decompensated congestive heart failure with marked bilateral leg edema one year later, the area of the healed ulcer remained tight and did not expand like adjacent areas.

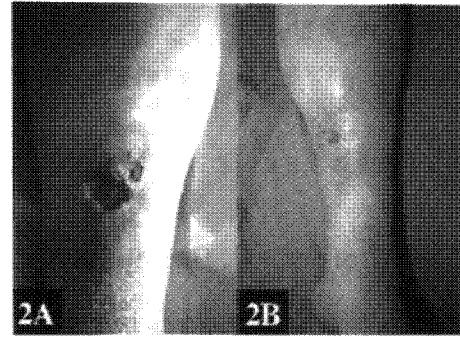


Fig 2: This 65-year-old woman had morbid obesity varicose veins. This otherwise healthy woman had an *ulcus cruris* which had been treated for 8 months in dermatology and surgery clinics. **A:** the pre-LLLT condition of the ulcer. **B:** the same ulcer completely healed after 2 months of LLLT. The ulcer remained healed one year later.

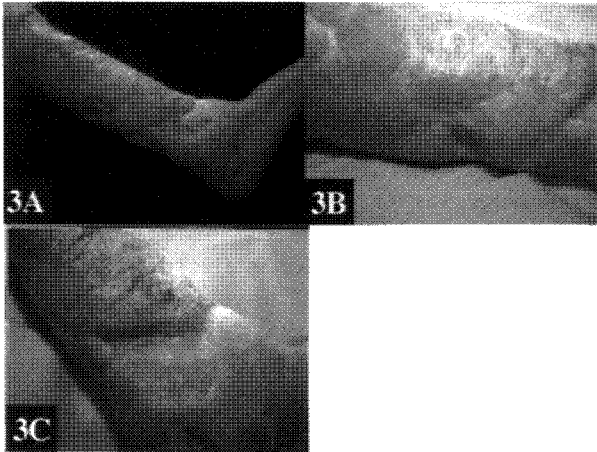


Fig 3: (left) This 75-year-old man had Parkinson's disease and malnutrition, with bilateral leg elephantiasis due to repeated erysipelas during 4 years in concentration camps. He developed numerous, extensive venous ulcers on both legs, primarily the right leg. He was treated conservatively and by repeated skin grafts in a plastic surgery clinic, and hospitalized periodically in medical wards with recurrent cellulitis. **A:** the leg after failure of conservative treatment, showing large deep ulcers. **B and C:** improvement after 144 treatments over 20 months. Deterioration in the status of his Parkinson's disease forced him to stop treatment. It is noteworthy that he was never hospitalized for cellulitis during the LLLT treatments.

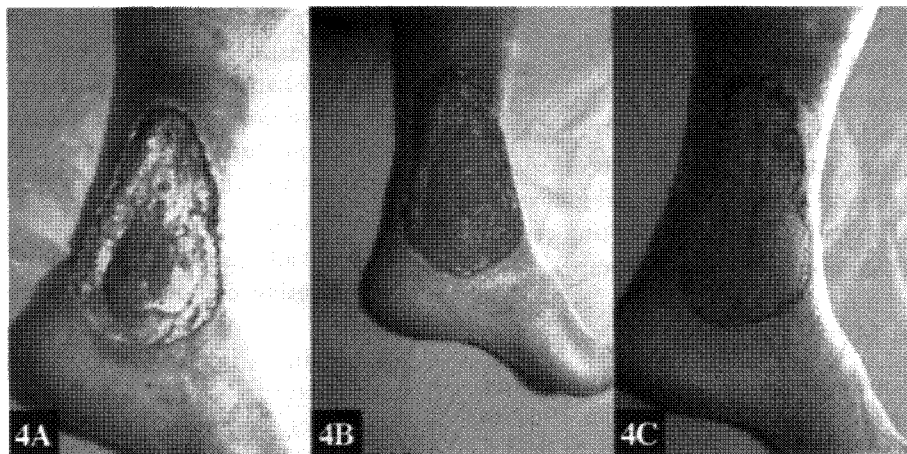


Fig 4: This 55-year-old pharmacist developed large varicose veins on both legs from long periods of having to remain standing. Nine months before referral he developed a deep, infected *ulcus cruris* that slowly worsened until he became incapacitated and began taking narcotics for pain. The ulcer reached the periosteum and a below-knee amputation was suggested. **A:** the leg at the beginning of LLLT treatments. **B:** full granulation after 5 months of treatment. **C:** 2 weeks after skin grafting. Nine months later the wound remains closed, pain and edema have disappeared and he has resumed work part-time in the pharmacy

B: A pulsed, scanning, double-beam laser type ML 300 (Medec, Switzerland), which has a combination of a visible red helium-neon (632.8 nm, 20 mW) laser and a gallium-aluminium-arsenide (GaAlAs) infrared laser (765 nm, 80 mW) with a pulse rate of from 0.1-10 kHz. This laser was applied in 13 patients with multiple wounds on the limb. The scanner beam was opened to cover the whole of the anterior aspect of the area, and was then aimed at the lateral or posterior aspect. Each area was irradiated at 4 kHz for 15 min every other day.

Outcome criteria

Outcome was classified as follows. Good: Complete cure with full wound closure; Moderate: partial wound closure but considerable improvement, in particular absence of pain and significant decrease in discharge, but patient decided to discontinue treatment; No effect: No improvement in the condition of the ulcer after receiving at least 2 weeks of treatment, and willingness to stop treatment.

Results

Four representative cases are presented in Figures 1 to 4. Please refer to the figure legends for details.

Wound Healing

Complete wound closure was achieved in 36 (85.7%) of 42 patients. Four patients improved significantly, but decided to stop treatment for various reasons. Two patients showed no improvement and the treatment was stopped after two weeks in one and after two months in the other. Complete wound closure was achieved in only one of two patients who underwent venous valve reconstruction. In two cases who showed moderate improvement, the ulcer turned out to be self inflicted.

The duration of treatment ranged from one to 9 months, mean 3.5 ± 0.66 months. The number of treatments ranged from 10 to 96, mean 34.7 ± 0.77 ; 2 severe cases were given 144 treatments over 20 months until good wound closure was achieved. The duration of treatments appeared to be correlated with the size of the wound, the number of wounds, and the general condition of the patient, although the small number of cases precludes drawing conclusions about this observation.

Follow-up

Thirty-five patients with complete wound healing were followed for 3 to 32 months, mean 19.29 ± 3.82 months. There were two incidences of recurrence of ulcers during the follow-up period In these 35 patients.

Discussion

Debilitating chronic stasis venous ulcers remain a challenge to the physician. Various modes of therapy have been used, including occlusive wound dressings, compression bandages, bed rest, and leg elevation.⁽⁷⁾ Topical glucocorticoid ointment has been used for localized venous dermatitis, and systemic antibiotics have been administered for bacterial cellulitis. In patients with severe venous disease, thrombolytic anticoagulant and antiaggregation therapies have been indicated. Pentoxifylline 400 mg t.i.d. has also been recommended to assist healing. In severe cases, skin grafting, application of growth factors, and hyperbaric oxygen have been recommended.⁽⁷⁾ Despite extensive experience with these approaches, the frequency of recurrence of ulcers and the accompanying pain and suffering attest to the lack of success of conventional modalities.

The effectiveness of LLLT in accelerating wound healing has been clinically documented in animal⁽⁶⁾ and clinical⁽⁹⁻¹¹⁾ studies. The putative mechanisms are improved metabolism of the affected tissue,⁽¹²⁾ increased collagen synthesis,⁽¹³⁾ enhanced cell proliferation, increased tensile strength, and improved proliferative phase of the repair process.^(14,15) LLLT might even be considered an extrinsic 'growth factor' which is capable of accelerating wound healing.

Our results with this modality were very encouraging, especially since our study population consisted of patients with long-lasting venous ulcers that had failed to respond to common conservative therapies. The improved tensile strength of the cured wound when compared to the texture of the initial pre-LLLT connective tissue⁽¹⁵⁾ may explain the almost complete absence of recurrence in our series. Moreover, in two of our patients who later developed decompensated congestive heart failure with marked bilateral leg edema, the area of the cured ulcer remained tight and did not expand like adjacent areas. This observation requires verification. In conclusion, our experience and that of others^(9,11) indicates that LLLT offers an effective treatment modality for patients with venous stasis ulcers. The treatment is painless, and no untoward effects have been reported after 30 years in use worldwide.

References

- 1: Baker SR, Stacey MC, and Jopp-McKay AG (1991): Epidemiology of chronic venous ulcers. *British Journal of Surgery*, 78: 864-667.
- 2: Bjordal R (1988): Flow and pressure studies in venous insufficiency. *Acta Chirurgica Scandinavica*, 544 (Suppl): 30-33.

- 3: McEnroe CS, O'Donnell TF, and Mackey WC (1988): Correlation of clinical findings with venous hemodynamics in 386 patients with chronic venous insufficiency. *American Journal of Surgery*, 156: 148-152.
- 4: Widmer LK, Mall TH, and Martin H (1993): Epidemiology and sociomedical importance of peripheral venous disease. In Hobbs JT (ed): *The Treatment of Venous Disorders*. Philadelphia: JB Lippincott Co., pp. 3-32.
- 5: Mester E, Ludany S, and Sellyei M (1968): The simulating effects of low power laser rays on biological systems. *Laser Review (London)*, 1: 3.
- 6: Mester E, Spiry T, Szende B, Tota JG (1971): Effect of laser rays on wound healing. *American Journal of Surgery*, 122: 532-535.
- 7: Burton III CS (1993): Management of chronic and problematic lower extremity wounds. *Dermatologic Clinics*, 11: 767-773.
- 8: Smith RJ, Birndorf M, and Gluck G (1992): The effect of low energy laser on skin-flap survival in the rat and porcine animal models. *Plastic Reconstruction and Surgery*, 89: 306-310.
- 9: Malm M, and Lundeborg T (1991): Effect of low power gallium arsenide laser on healing of venous ulcers. *Scandinavian Journal of Reconstructive Hand Surgery*, 25: 249-251.
- 10: Rochkind S, Ruosso M, and Nissan M (1989): Systemic effects of low-power laser irradiation on the peripheral and central nervous system, cutaneous wounds, and burns. *Laser In Surgery and Medicine*, 9: 174-182.
- 11: Tefler J, Filomenko N, Salansky N (1993): Low energy laser therapy for leg ulcers. *Lasers in Surgery and Medicine (Suppl)* 5: 56.
- 12: Basford JR (1995): Low intensity laser therapy. *Laser Surgery and Medicine*, 16: 331-342.
- 13: Saperia D, Glassberg E, and Lyons RF (1986): Demonstration of elevated type I and III pro collagen mRNA levels in cutaneous wounds treated with helium-neon laser: proposed mechanism for enhanced wound healing. *Biochemical and Biophysics Research Communication*, 138: 1123-1128.
- 14: Abergel RP, Lyons RF, and Castel JC (1987): Biostimulation of wound healing by lasers: experimental approaches in animal models and in fibroblast cultures. *Journal of Dermatology and Surgery in Oncology*, 13: 127-133.
- 15: Germain L, Jean A, Auger FA, and Garrel DR (1994): Human wound healing fibroblasts have greater contractile properties than dermal fibroblasts. *Journal of Surgical Research*, 57: 266-273.